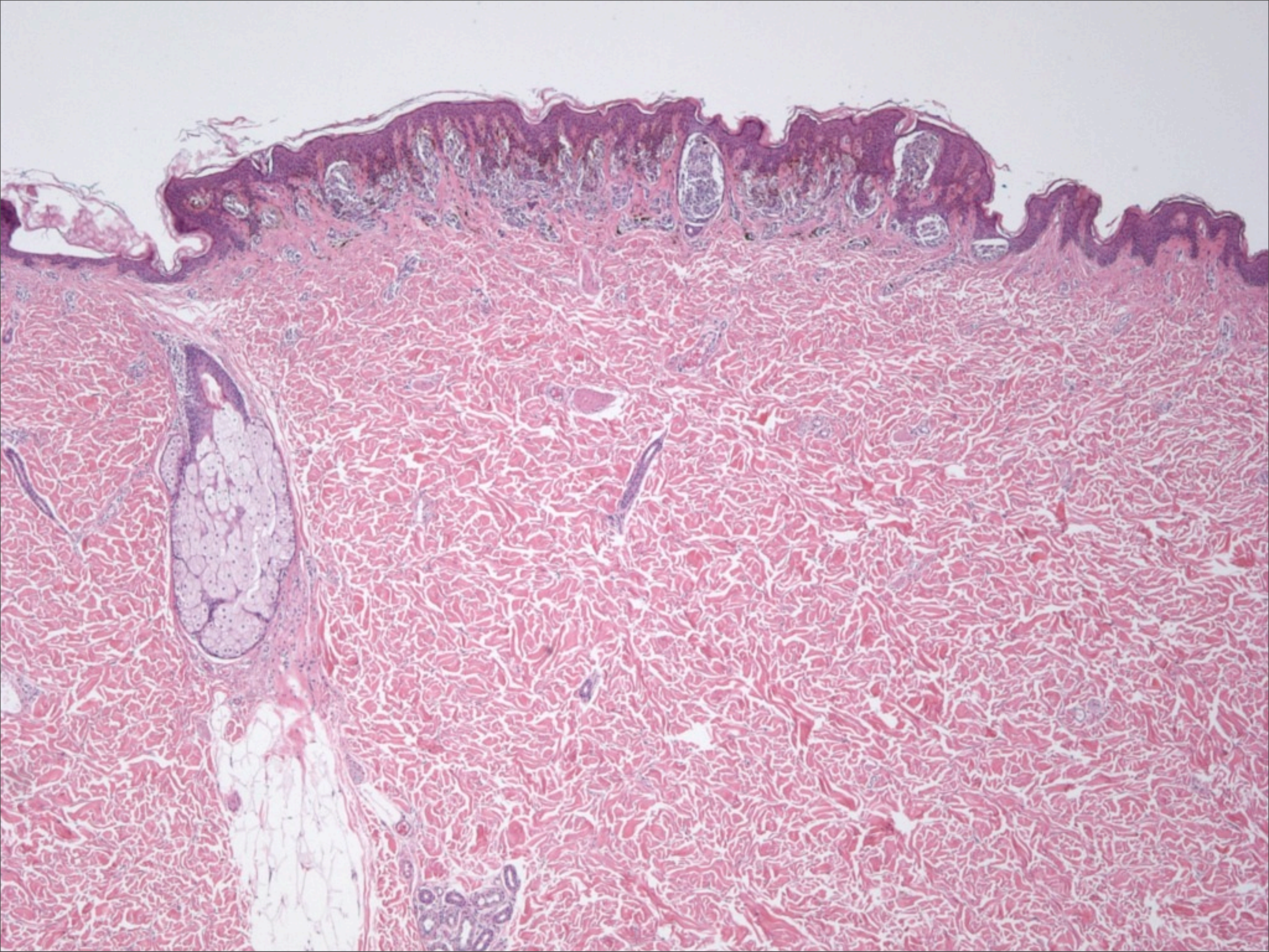
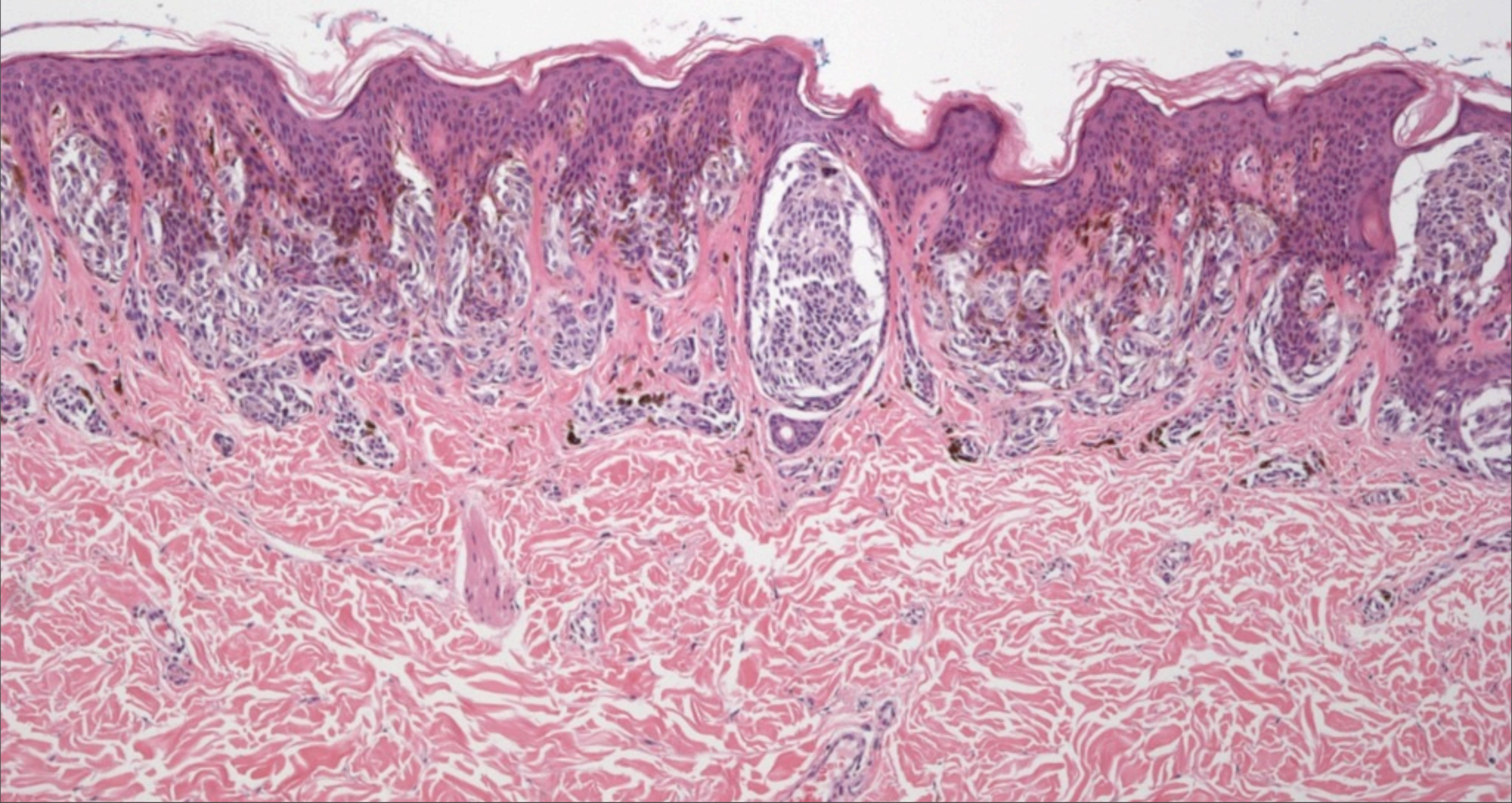
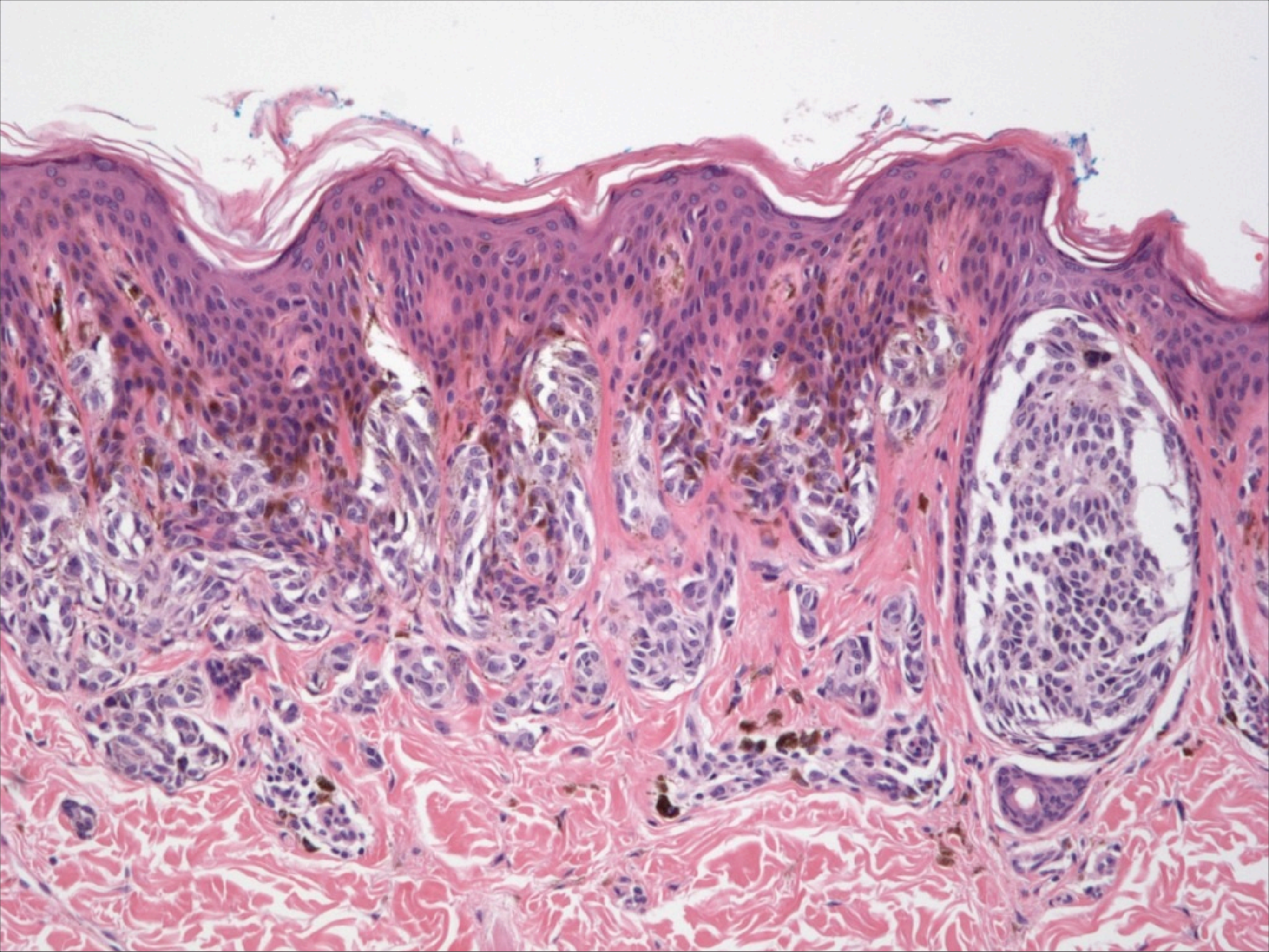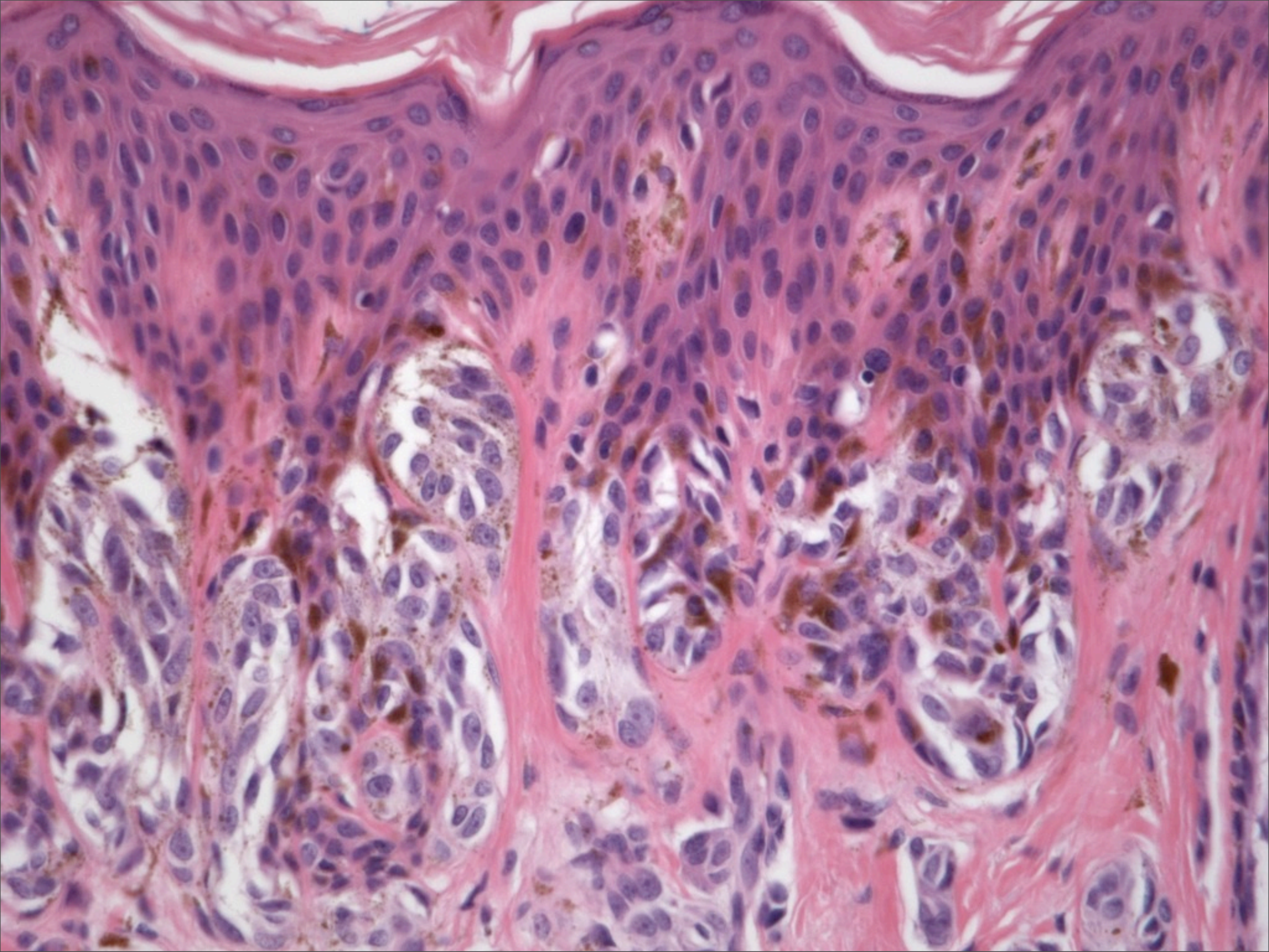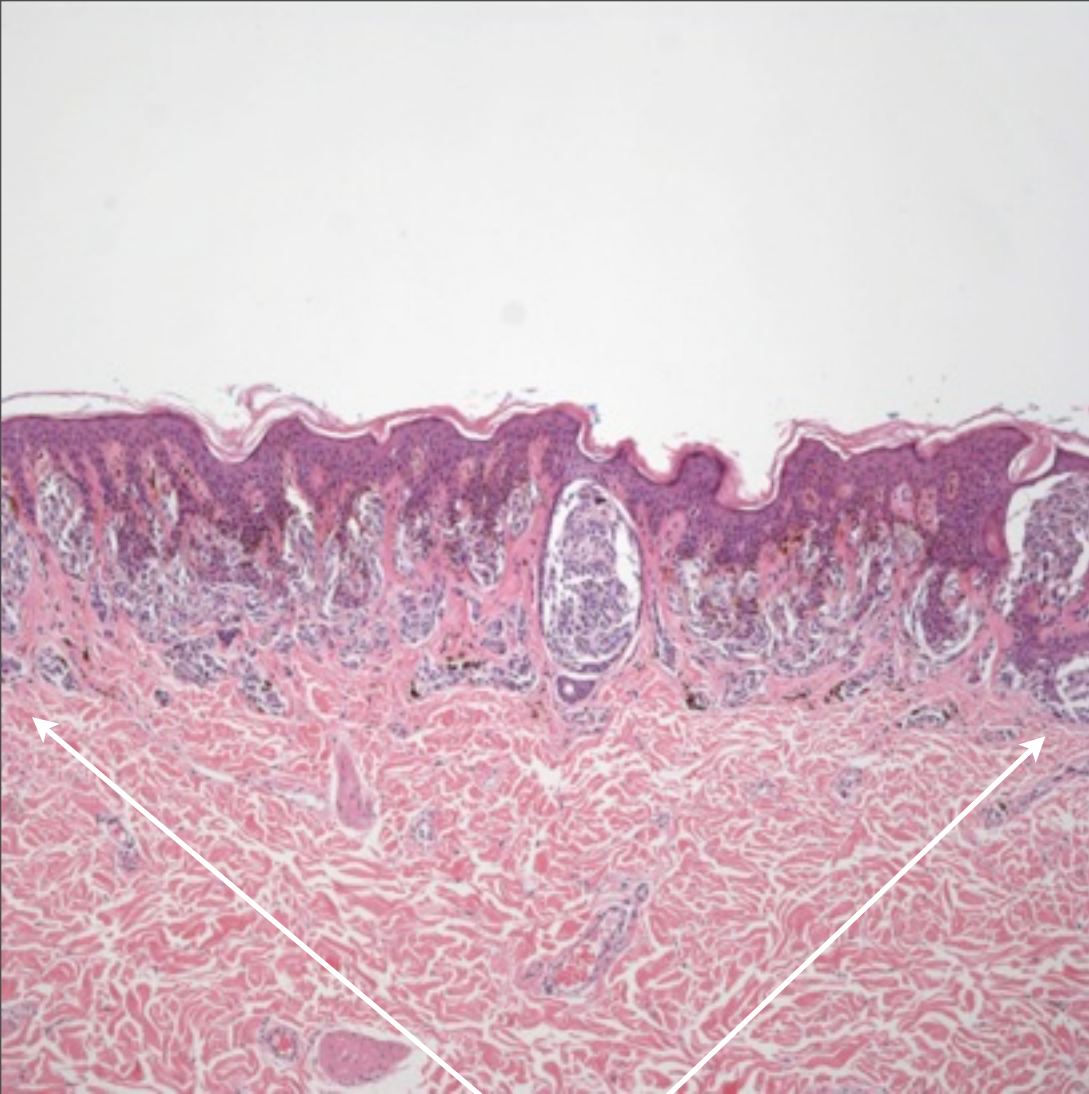


# Pigmented Spindle Cell Nevus

Pigmented spindled and  
epithelioid melanocytes

Minimal cytologic atypia

Kamino bodies rarely



Sharp peripheral circumscription